

Report

Different Mutations in the LMNA Gene Cause Autosomal Dominant and Autosomal Recessive Emery-Dreifuss Muscular Dystrophy

Marina Raffaele di Barletta,¹ Enzo Ricci,^{2,3} Giuliana Galluzzi,⁴ Pietro Tonali,² Marina Mora,⁵ Lucia Morandi,⁵ Alessandro Romorini,⁶ Thomas Voit,⁷ Karen Helene Orstavik,⁸ Luciano Merlini,⁹ Carlo Trevisan,¹⁰ Valerie Biancalana,¹³ Irena Housmanowa-Petrusewicz,¹¹ Silvia Bione,¹ Roberta Ricotti,¹ Ketty Schwartz,¹² Giselle Bonne,¹² and Daniela Toniolo¹

¹Institute of Genetics Biochemistry and Evolution–Consiglio Nazionale delle Ricerche, Pavia, Italy; ²Institute of Neurology, Catholic University, ³Centre for Neuromuscular Diseases, UILDM–Rome Section, and ⁴Institute of Cell Biology–CNR, Rome; ⁵Istituto Neurologico Besta, Milan; ⁶Legnano Hospital, Legnano, Italy; ⁷Department of Pediatrics, University of Essen, Essen, Germany; ⁸Department of Medical Genetics, Ullevål Hospital, Oslo; ⁹Rizzoli Institute, Bologna; ¹⁰Department of Clinical Neurology, University of Padova, Padova, Italy; ¹¹Medical Research Center, Polish Academy of Science, Warsaw; ¹²INSERM UR153 and Institut de Myologie, GH Pitié-Salpêtrière, Paris; ¹³Service de Génétique, Strasbourg University Medical School, Strasbourg, France

Emery-Dreifuss muscular dystrophy (EMD) is a condition characterized by the clinical triad of early-onset contractures, progressive weakness in humeroperoneal muscles, and cardiomyopathy with conduction block. The disease was described for the first time as an X-linked muscular dystrophy, but autosomal dominant and autosomal recessive forms were reported. The genes for X-linked EMD and autosomal dominant EMD (AD-EMD) were identified. We report here that heterozygote mutations in LMNA, the gene for AD-EMD, may cause diverse phenotypes ranging from typical EMD to no phenotypic effect. Our results show that LMNA mutations are also responsible for the recessive form of the disease. Our results give further support to the notion that different genetic forms of EMD have a common pathophysiological background. The distribution of the mutations in AD-EMD patients (in the tail and in the 2A rod domain) suggests that unique interactions between lamin A/C and other nuclear components exist that have an important role in cardiac and skeletal muscle function.

Emery-Dreifuss muscular dystrophy (EMD) (MIM 310300 and 310200) is a condition characterized by the clinical triad of early-onset contractures, progressive weakness in humeroperoneal muscles, and cardiomyopathy with conduction block (Emery 1989; Toniolo et al. 1998). It is important to recognize EMD as separate disorder, because the disease is associated with life-threatening cardiomyopathy that can be managed by insertion of cardiac pacemakers. The disease was described for the first time as an X-linked disorder (Emery and Dreifuss 1966), and members of many families who showed X-linked recessive inheritance were later described. Autosomal dominant (Fenichel et al. 1982; Miller et al. 1985; Yates 1997) and autosomal recessive

forms (Takamoto et al. 1984; Taylor et al. 1998) of EMD were also reported. As the clinical symptoms are very similar, it has been suggested that the different genetic forms may have a common pathophysiological background.

The genes for X-linked (X-EMD) and autosomal dominant EMD (AD-EMD) have been identified (Bione et al. 1994; Bonne et al. 1999). The X-EMD gene encodes emerin, a ubiquitous protein localized, in most cell types, to the inner nuclear membrane (Nagano et al. 1996; Cartegni et al. 1997; Manilal et al. 1998; Morris and Manilal 1999). Emerin most likely interacts with the nuclear lamina, a mesh of intermediate filaments (the lamins) that constitute the nuclear cytoskeleton (Stuurman et al. 1998). AD-EMD is caused by mutations in the gene LMNA, which encodes two lamins, A and C, by differential maturation of the 3' end of the mRNA (Lin and Worman 1993). The finding that lamin A/C and emerin mutations are responsible for clinically similar disorders shows that in skeletal muscle and heart,

Received December 14, 1999; accepted for publication February 14, 2000; electronically published March 16, 2000.

Address for correspondence and reprints: Dr. Daniela Toniolo, Institute of Genetics, Biochemistry and Evolution–CNR, Via Abbiategrasso 207, 27100 Pavia, Italy. E-mail: Toniolo@igbe.pv.cnr.it

© 2000 by The American Society of Human Genetics. All rights reserved.
0002-9297/2000/6604-0023\$02.00

interactions between nuclear membrane components are critical for skeletal and cardiac muscle function, and loss of integrity of the nuclear envelope is an underlying cause of muscular dystrophy.

From the study of mutations in the LMNA gene in selected AD-EMD pedigrees, it was apparent that the clinical manifestations in individuals affected by AD-EMD could be quite different from those with the typical EMD phenotype (Bonne et al. 1999). We have, therefore, investigated additional cases of AD-EMD, to extend the number of known mutations and to look for phenotype-genotype correlations. Most of the patients we studied were males who had been referred for diagnosis of X-EMD. Few were familial cases; the majority were sporadic (table 1). Only some of the patients had a classical EMD phenotype (patients TB, FG, AH, and CE-30); others were diagnosed as atypical EMD (DPC and PD) or as affected by congenital muscular dystrophy, limb girdle muscular dystrophy, or rigid-spine syndrome. The cardiac involvement was also heterogeneous. Both bradyarrhythmias (which frequently required pacemaker implantation) and tachyarrhythmias were observed in patients (table 1). In some patients, dilated cardiomyopathy (DCM) or restrictive cardiomyopathy (RCM) were reported (table 1). Patient Rb was diagnosed at age 31 years after severe heart block. Echocardiography showed mild DCM. Patient II-1 is a member of a family that will be described in detail elsewhere

(Brodsky et al. 2000); the patient presented with severe DCM and variable skeletal muscle involvement. Patient DPC, in whom a pacemaker had been implanted when he was 41 years old, died of sudden cardiac arrest at age 49 years. Finally, some patients (for example, MG, at age 40 years) did not show evidence of cardiac involvement.

In all patients, mutations in the X-linked emerin gene were excluded by sequence analysis (Bione et al. 1995). A set of 27 primers was used to PCR-amplify all exons and exon-intron junctions of the LMNA gene, as described elsewhere (Bonne et al. 1999). Because we found recurrent mutations, the strategy for mutation detection was to use direct sequencing of PCR products for exons 6–9 and to analyze the rest of the gene by single strand conformation polymorphism (SSCP). PCR products of exons showing band shifts were sequenced. Mutations in the LMNA gene were found in 13 patients of the 25 we analyzed (table 1). Only one patient, II-1, had a 1-bp deletion (960delT); all other mutations were non-conservative modifications of highly conserved amino acid residues (data not shown). In most instances, the mutations also caused a change in the amino acid charge that could disrupt the highly organized structure of the lamins (Stuurman et al. 1998). Absence of the mutations among 100 chromosomes of individuals not presenting the phenotype was determined by restriction-enzyme digestion or by denaturing high-performance liquid chro-

Table 1

Patients Analyzed

Patient	Age (years)	Sex	Inheritance	Diagnosis	Cardiac Involvement	Mutation	Exon	Effect of Mutation	Reference
MG	40	M	Sporadic	X-EMD or CMD	None	C644T	4	H222Y	...
FG	17	M	Sporadic	X-EMD	Pacemaker at age 16 years	G746A	4	R249Q	...
CE-30	33 ^a	M	Sporadic	X-EMD	AV block	G746A	4	R249Q	...
Rb	31	M	Sporadic	X-EMD	Pacemaker at 31 years + DCM	G746A	4	R249Q	...
II-1	...	M	Familial	LGMD1A + EMD	DCM	960delT	6	FS from R321	Brodsky et al. (2000)
PD	16	M	Sporadic	EMD	None	G1007A	6	R336Q	...
DPC	49 ^a	M	Sporadic	EMD	Pacemaker at 41 years + RCM	C1357T	7	R453W	...
MS	39	M	Sporadic	X-EMD or RSS	Pacemaker at 31 years	C1357T	7	R453W	Voit et al. (1988)
LC	42	M	Sporadic	X-EMD or RSS	Tachyarrhythmia and AV block	C1357T	7	R453W	...
21a-III/5	21	M	Sporadic	X-EMD	None	C1357T	7	R453W	...
AH	31	F	Familial	AD-EMD	Pacemaker at age 28 years	T1406C	8	I469T	Orstavik et al. (1990)
TB	58	M	Sporadic	X-EMD	Pacemaker at age 43 years	G1580C	9	R527P	...
GC	23	M	Sporadic	X-EMD or RSS	Tachyarrhythmia and AV block	C1583A	9	T528K	...

NOTE.—CMD = congenital muscular dystrophy; AV = atrioventricular; DCM = dilated cardiomyopathy; F = female; M = male; RSS = rigid spine syndrome; RCM = restrictive cardiomyopathy.

^a Age at death.

matography (DHPLC) (Oefner and Underhill 1995, 1998).

Our analysis showed that, in addition to AD-EMD, the LMNA gene is responsible for AR-EMD and for a semidominant form of the disorder. Both SSCP and sequence analysis (fig. 1a) demonstrated that patient MG (table 1) was a homozygote for the mutation C664T, causing the amino acid change H222Y in a histidine conserved from human to chicken and in lamin B1 (data not shown). Sequence analysis of the rest of the LMNA gene in the patient demonstrated that C664T was the only mutation. His parents, who were first cousins, were heterozygotes. The mutation was not found among 200 chromosomes of individuals unaffected by EMD that we analyzed by DHPLC.

Patient MG presented with a very severe form of muscular dystrophy that had been diagnosed either as an atypical EMD or as congenital muscular dystrophy. The patient experienced difficulties when he started walking at age 14 mo; at age 5 years, he could not stand because

of contractures. At age 40 years, he presented severe and diffuse muscle wasting and was confined to a wheelchair. His intelligence was normal; careful cardiological examination showed that he did not have cardiac problems. His parents were unaffected. They had had recent clinical and cardiological examinations, including electrocardiograms, echocardiographs, and Holter electrocardiograms. None of them presented skeletal muscle or cardiac alterations.

DNA from family members of sporadic patients was analyzed (when it was available) to determine whether some of the relatives, especially the very young ones, might be carriers of the mutation or might be mildly or not yet affected. Patient PD carried a R366Q amino acid change (table 1). Analysis of the patient's family members showed that the mutation was present in the proband's grandmother and mother and in one of the sisters (fig. 1b). After we found the mutation, we carefully examined these family members for the presence of clinical symptoms. At the time of the study, the proband's grand-

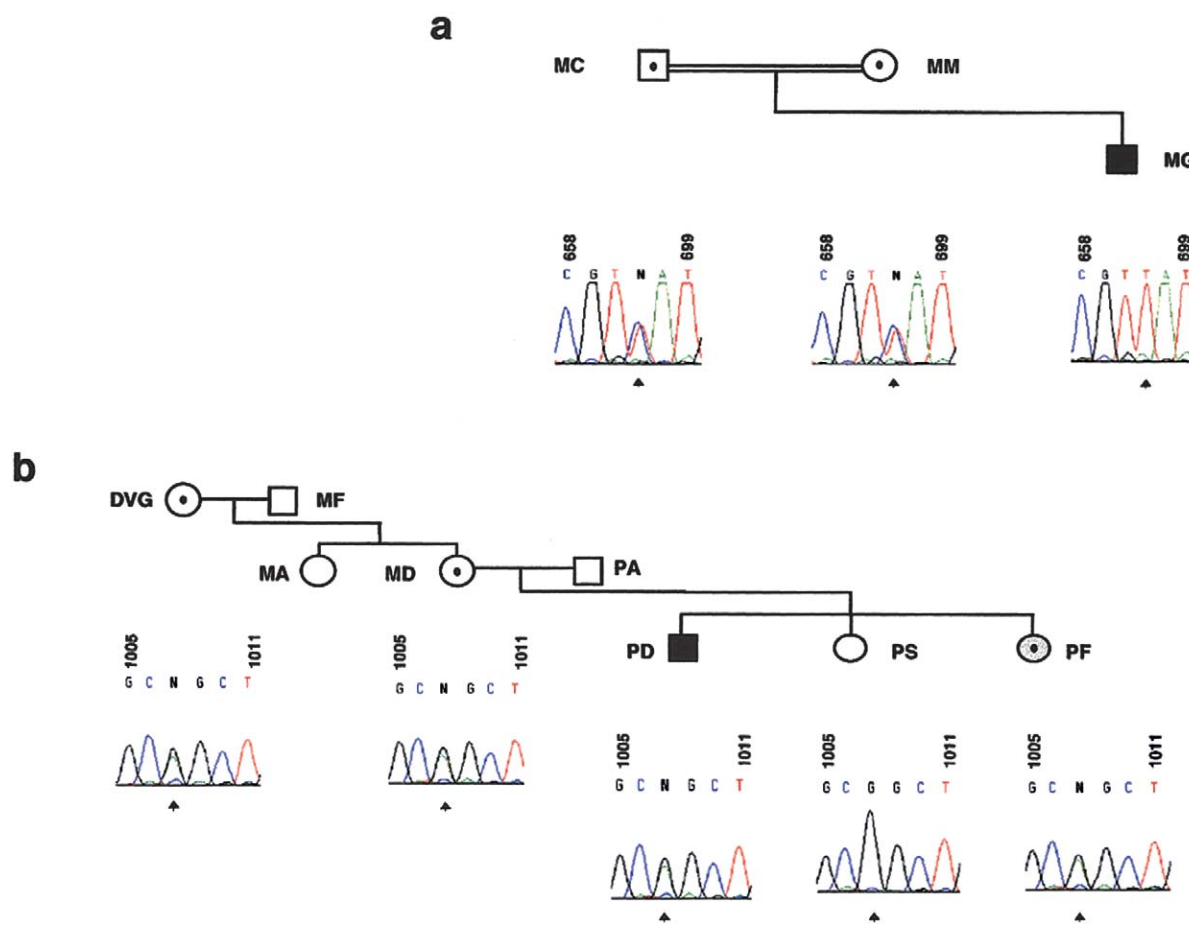


Figure 1 Chromatograms of the portions of the sequencing gels showing the presence of mutations below the pedigrees of the families of patient MG (a) and of patient PD (b). The position of the mutation is indicated (arrow). Sequences were performed and analyzed as described by Bione et al. (1995).

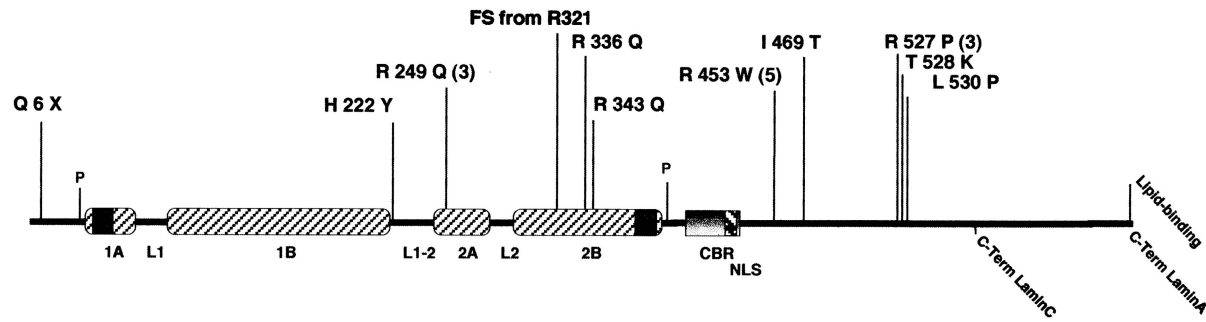


Figure 2 Schematic representation of the structural organization of lamin A/C and of the position of the mutations found. The four mutations described by Bonne et al. (1999) are Q6X, R453W, R527P (2X), and L530P. When mutations were found repeatedly, the number of patients is indicated in brackets. α -helical regions are shown (*slash marks*), as are conserved sequences in 1A and 2B (*blackened squares*). CBR = chromatin-binding region; NLS = nuclear localization signal.

mother was 80 years old and healthy, as was the proband's mother at age 40 years. The proband's sister had slightly elevated creatine kinase levels and no other symptoms at age 12 years. All the exons of patient PD were examined by direct sequencing, but no other mutation was found. To exclude the possibility that the mutation was a polymorphism, 200 chromosomes of unaffected individuals were analyzed by DHPLC. We did not find the mutation in the unaffected population.

Patient PD had a very mild disorder: he showed early Achilles-tendon contractures and very mild, nonprogressive pelvic-girdle muscle weakness. Lumbar spine rigidity and retraction of the elbows started at age 13 years. At age 17 years, neurological examination showed moderate rigid spine, bilateral elbow retraction and equinism, and mild pelvic-girdle weakness. Cardiologic examination indicated that the proband's heart was normal. The appearance of a mild phenotype in the third generation, in the absence of a second mutation in LMNA, suggested the existence of a modifier gene or genes that may have been responsible for the heterogeneity of the phenotype (Toniolo et al. 1998; Bonne et al. 1999).

In summary, the mutation analysis of the LMNA gene in patients affected with EMD showed that mutations in LMNA caused a range of diverse phenotypes and a larger clinical variability than that observed for X-EMD. We definitively demonstrated the existence of AR-EMD, and we showed that, in the same pedigree, a mutation may have different penetrance and behave either as dominant or as recessive. Our results indicate that the LMNA gene should be studied, in the absence of a typical EMD phenotype, in all patients presenting early contractures of humeroperoneal muscle, a rigid spine, or both. Differences caused by penetrance of the mutations may complicate the diagnosis and must be taken into account.

We analyzed a small group of patients referred for diagnosis of X-EMD. Mutations in LMNA suggest that patients affected with AD-EMD are underdiagnosed and

that their number is likely higher than predicted from family studies. The number of isolated cases in our sample (11 of 13) also suggest that the frequency of new mutations may be higher for AD-EMD than X-EMD (Yates 1997).

Among the dominant mutations described in this study and in Bonne et al. (1999), the majority were amino acid changes that could result in a dominant negative effect. It is significant that recurrent changes were observed in AD-EMD patients: 11 of 16 (68%) dominant mutations causing AD-EMD were localized to the central region of the tail domain, and three of the remaining five patients carried the same mutation in the 2A rod domain (fig. 2). Fatkin et al. (1999) recently described mutations in LMNA in patients affected with DCM and with conduction system disorders but who did not present with contractures or skeletal myopathy: four mutations were in rod domain 1 and one in the tail of lamin C. Lamins are involved in multiple interactions with themselves (Stuurman et al. 1998), with proteins of the nucleus of the nuclear envelope (Foisner and Gerace 1993; Martin et al. 1995; Furukawa et al. 1997; Worman et al. 1988), and with chromatin (Hoger et al. 1991; Glass et al. 1993; Taniura et al. 1995). The different distribution along lamin A/C of the mutations in AD-EMD and DCM patients suggests that the tail domain and the two rod domains of lamin A/C participate in different interactions in skeletal or cardiac muscle. This interpretation can also explain the finding of a mutation in patients affected with Dunnigan-type familial partial lipodystrophy, a disorder of adipocytes associated with insulin resistance and diabetes but not with muscular or cardiac alterations (Cao and Hegele 2000). This very unexpected finding suggests that the interactions of lamin A/C may be diverse in different cell types and that specific mutations may modify some of the interactions, eventually causing tissue or cell-type-specific alterations of the nuclear envelope.

How does a lamin defect cause EMD? Most mutations

affecting emerin are null (Morris and Manilal 1999), and lack of emerin seems to be the cause of X-EMD. It has been suggested that haploinsufficiency or a dominant negative effect caused by mutations in lamin A/C modifies the nuclear lamina and the nuclear envelope and causes, either directly or indirectly, misplacement or modifications of the distribution of emerin (Toniolo and Minetti 1999). Alternatively, a third component, in addition to emerin and lamin A/C, may exist, and its cellular distribution may be altered by lack of emerin and by mutations in lamin A/C. From this point of view, the recently published study of mice lacking lamin A (Sullivan et al. 1999) is of great interest. Soon after birth, the *Lmna* $-/-$ mice develop severe muscular dystrophy; their phenotype is associated with ultrastructural perturbations of the nuclear envelope and mislocalization of emerin. Another nuclear envelope protein, LAP2, which is known to interact with chromatin and B-type lamins (Foisner and Gerace 1993) but not with lamin A/C, was found at the nuclear envelope. Study of specific *Lmna* mutations in the mouse model in the heterozygotic and homozygotic state may help clarify the role of and the interactions of lamin A/C in different affected tissues.

Acknowledgments

We thank the patients we studied and their families for their collaboration. We thank the European Neuromuscular Center for its support. We also thank Luisa Maestroni for providing the DNA of patient II-1 and Luisa Maestroni and Francesco Muntoni for unpublished data on the clinical characterization of the family of patient II-1. The research was funded by Tel-ethon, Italy (D.T.), and by the Ministero dell'Università e della Ricerca Scientifica (E.R.).

Electronic-Database Information

Accession numbers and URLs for data in this article are as follows:

Online Mendelian Inheritance in Man (OMIM), <http://www.ncbi.nlm.nih.gov/Omim> (for EMD [MIM 310300 and 310200])

Human Gene Mutation Database, <http://www.uwcm.ac.uk/search/mg/allgenes> (for emerin mutations)

References

- Bione S, Maestrini M, Rivella S, Mancini M, Regis S, Romeo G, Toniolo D (1994) Identification of a novel X-linked gene responsible for Emery Dreifuss muscular dystrophy. *Nat Genet* 8:323–327
- Bione S, Small K, Aksmanovic VMA, D'Urso M, Ciccodicola A, Merlini L, Morandi L, et al (1995) Identification of new mutations in the Emery-Dreifuss muscular dystrophy gene and evidence for genetic heterogeneity of the disease. *Hum Mol Genet* 4:1859–1863
- Bonne G, Raffaele di Barletta M, Varnous S, Becane HM, Hammouda EH, Merlini L, Muntoni F, et al (1999) Mutations in the gene encoding lamin A/C cause autosomal dominant Emery-Dreifuss muscular dystrophy. *Nat Genet* 21:285–288
- Brodsky GL, Muntoni F, Miodic S, Sinagra G, Sewry C, Maestroni L (2000) Lamin A/C gene mutation associated with dilated cardiomyopathy with variable skeletal muscle involvement. *Circulation* 101:473–476
- Cao H, Hegele RA (2000) Nuclear lamin A/C R482 mutation in Canadian kindreds with Dunnigan-type familial partial lipodystrophy. *Hum Mol Genet* 9:109–112
- Cartegni L, Raffaele di Barletta M, Barresi R, Squarzoni S, Sabatelli P, Maraldi N, Mora M, et al (1997) Heart-specific localization of emerin: new insights into Emery-Dreifuss muscular dystrophy. *Hum Mol Genet* 6:2257–2264
- Emery AEH (1989) Emery-Dreifuss syndrome. *J Med Genet* 26:637–641
- Emery AEH, Dreifuss FE (1966) Unusual type of benign X-linked muscular dystrophy. *J Neurol Neurosurg Psychiatry* 29:338–342
- Fatkin D, MacRae C, Sasaki T, Wolff MR, Porcu M, Frenneaux M, Atherton J, et al (1999) Missense mutations in the rod domain of the lamin A/C gene as causes of dilated cardiomyopathy and conduction system disease. *N Engl J Med* 341:1715–1724
- Fenichel GM, Sul YC, Kilroy AW, Blouin R (1982) An autosomal-dominant dystrophy with humeroperoneal distribution and cardiomyopathy. *Neurology* 32:1399–1401
- Foisner R, Gerace L (1993) Integral membrane proteins of the nuclear envelope interact with lamins and chromosomes, and binding is modulated by mitotic phosphorylation. *Cell* 73:1267–1279
- Furukawa K, Glass C, Kondo T (1997) Characterization of the chromatin binding activity of lamina-associated polypeptide (LAP) 2. *Biochem Biophys Res Commun* 238:240–246
- Glass CA, Glass JR, Taniura H, Hasel KW, Blevitt JM, Gerace L (1993) The α -helical rod domain of human lamins A and C contains a chromatin binding site. *EMBO J* 12:4413–4424
- Hoger TH, Krohne G, Kleinschmidt JA (1991) Interaction of *Xenopus lamins* A and LII with chromatin in vitro mediated by a sequence element in the carboxyterminal domain. *Exp Cell Res* 197:280–289
- Lin F, Worman HJ (1993) Structural organization of the human gene encoding nuclear Lamin A and nuclear Lamin C. *J Biol Chem* 268:16321–16326
- Manilal S, Recan D, Sewry CA, Hoeltzenbein M, Llense S, Leturcq F, Deburgrave N, et al (1998) Mutations in Emery-Dreifuss muscular dystrophy and their effects on emerin protein expression. *Hum Mol Genet* 7:855–864
- Martin L, Crimando C, Gerace L (1995) cDNA cloning and characterization of lamina-associated polypeptide 1C (LAP1C), an integral protein of the inner nuclear membrane. *J Biol Chem* 270:8822–8828
- Miller RG, Layzer RB, Mellenthin MA, Golabi M, Francoz RA, Mall JC (1985) Emery-Dreifuss muscular dystrophy with autosomal dominant transmission. *Neurology* 35:1230–1233
- Morris GE, Manilal S (1999) Heart to heart: from nuclear proteins to Emery-Dreifuss muscular dystrophy. *Hum Mol Genet* 8:1847–1851

- Nagano A, Koga R, Ogawa M, Kurano Y, Kawada J, Okada R, Hayashi YK, et al (1996) Emerin deficiency at the nuclear membrane in patients with Emery-Dreifuss muscular dystrophy. *Nat Genet* 12:254–259
- Oefner PJ, Underhill PA (1995) Comparative DNA sequence by denaturing high performance liquid chromatography (DHPLC). *Am J Hum Genet Suppl* 57:266
- Oefner PJ, Underhill PA (1998) Comparative DNA mutation detection using denaturing high performance liquid chromatography (DHPLC). In: Dracopoli NC, Haines JL, Korf BR, Moir DT, Morton CC, Seidman CE, Seidman JG, et al (eds) *Current protocols in human genetics*, Wiley, New York, pp 7.10.1–7.10.12
- Orstavik KH, Kloster R, Lippestad C, Rode L, Hovig T, Fuglseth KN (1990) Emery-Dreifuss syndrome in three generations of females, including identical twins. *Clin Genet* 38:447–451
- Stuurman N, Heins S, Aebi U (1998) Nuclear lamins: their structure, assembly and interactions. *J Struct Biol* 122:42–66
- Sullivan T, Escalante-Alcade D, Batt H, Anver M, Bhat N, Nagashima K, Stewart CL, et al (1999) Loss of A-type lamin expression compromises nuclear envelope integrity leading to muscular dystrophy. *J Cell Biol* 147:913–920
- Takamoto K, Hirose K, Uono M, Nokana I (1984) A genetic variant of Emery-Dreifuss disease. *Arch Neurol* 41:1292–1293
- Taniura H, Glass C, Gerace L (1995) A chromatin binding site in the tail domain of nuclear lamins that interacts with core histone. *J Cell Biol* 131:33–44
- Taylor J, Sewry CA, Dubowitz V, Muntoni F (1998) Early onset autosomal recessive muscular dystrophy with Emery-Dreifuss phenotype and normal emerin expression. *Neurology* 51:1116–1120
- Toniolo D, Bione S, Arahata K (1998) Emery-Dreifuss muscular dystrophy. In: Emery AEH (ed) *Neuromuscular disorders: clinical and molecular genetics*. Wiley, London, pp 87–103
- Toniolo D, Minetti C (1999) Muscular dystrophies: alterations in a limited number of cellular pathways? *Curr Opin Genet Dev* 9:275–282
- Voit T, Krogman O, Lenard HG, Neuen-Jacob E, Wechsler W, Goebel HH, Rahlf G, et al (1988) EMD: disease spectrum and differential diagnosis. *Neuropediatrics* 19:62–71
- Worman HJ, Yuan J, Blobel G, Georgatos SD (1988) A lamin B receptor in the nuclear envelope. *Proc Natl Acad Sci USA* 85:8531–8534
- Yates JR (1997) 43rd ENMC International Workshop on Emery-Dreifuss muscular dystrophy. *Neuromuscul Disord* 7:67–69